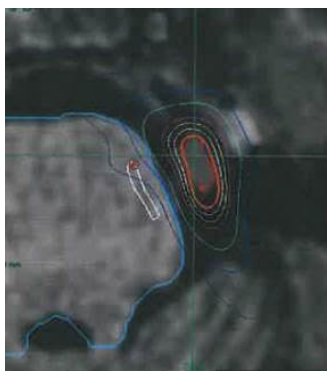



CyberKnife® Stereotactic Radiosurgery for Trigeminal Neuralgia



CyberKnife, no fixed metal headframe



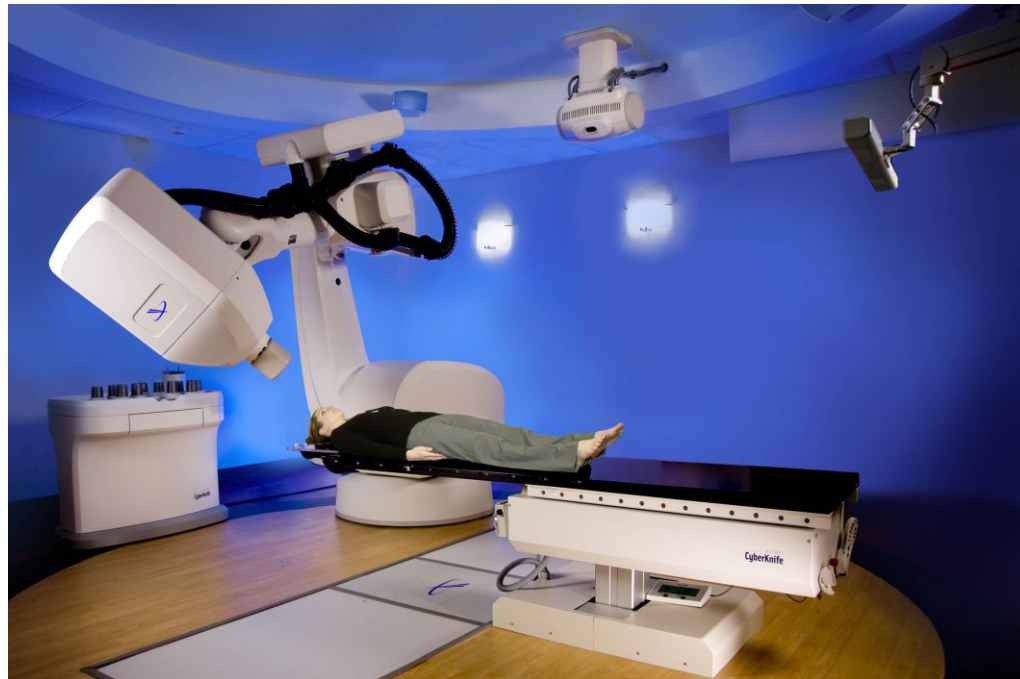Left Trigem nerve treatment plan view



Dose distribution treatment plan

Austin CyberKnife treats several different types of malignant and benign tumors in the brain, spine, lung, liver, pancreas, prostate and kidney as well as certain medical conditions like trigeminal neuralgia and arteriovenous malformations. Our center is dedicated to providing patients with the latest cancer treatment technology, and we're proud of the experience and clinical expertise our physicians and caring staff bring to our patients. Most insurance plans and Medicare are accepted.

The information contained in this document is presented in summary form only and is not intended to replace or serve as a substitute for your duty to verify that such information is proper for your patients signs, symptoms, conditions or circumstance(s).



HISTORY

The patient is a 62 year old female with left-sided facial pain for more than four years. The pain originates at the left upper lip and radiates back toward the left ear. She describes it as intense and shock-like with a pain scale rating of 10 out of 10. The pain is initiated and exacerbated by eating, talking and brushing her teeth or by touch. After an initial evaluation by her dentist with no dental issues identified, her primary care physician prescribed pain medication gradually increasing the dose over time. Although she initially responded to medications, she became refractory over time.

CONSULTATION & DIAGNOSIS

The patient was diagnosed with classical left-sided trigeminal neuralgia affecting the maxillary branch. Based on review of her case, the patient is a good candidate for treatment using CyberKnife Radiosurgery. A CT scan and MRI-RTP will be utilized in the treatment planning, scheduled to be complete in one visit (fraction).

TREATMENT

The patient underwent painless, noninvasive stereotactic radiosurgery outpatient treatment. The CyberKnife technology utilized an optimized plan with 65 nodes and 113 beams, to deliver 75 Gy in one treatment.

RESULTS

Status 6 months post CyberKnife stereotactic radiosurgery ablation of the left-sided trigeminal nerve root, the patient has demonstrated a good response. She is completely weaned from neuroleptic medications and has been released by her neurologist. Routine follow up will occur in another 6 months.

A U S T I N
CYBERKNIFE®

A Department of University Medical Center Brackenridge

